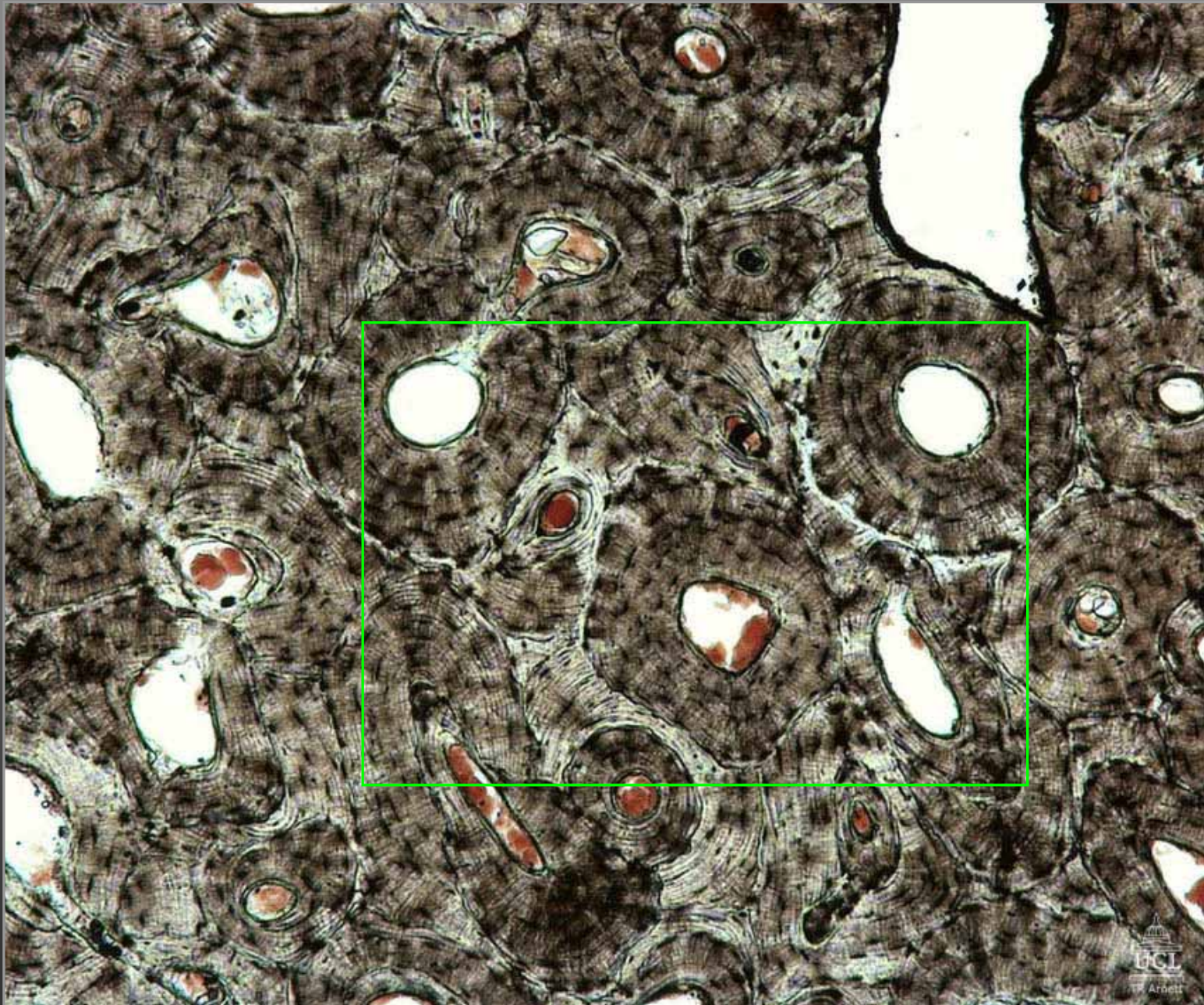
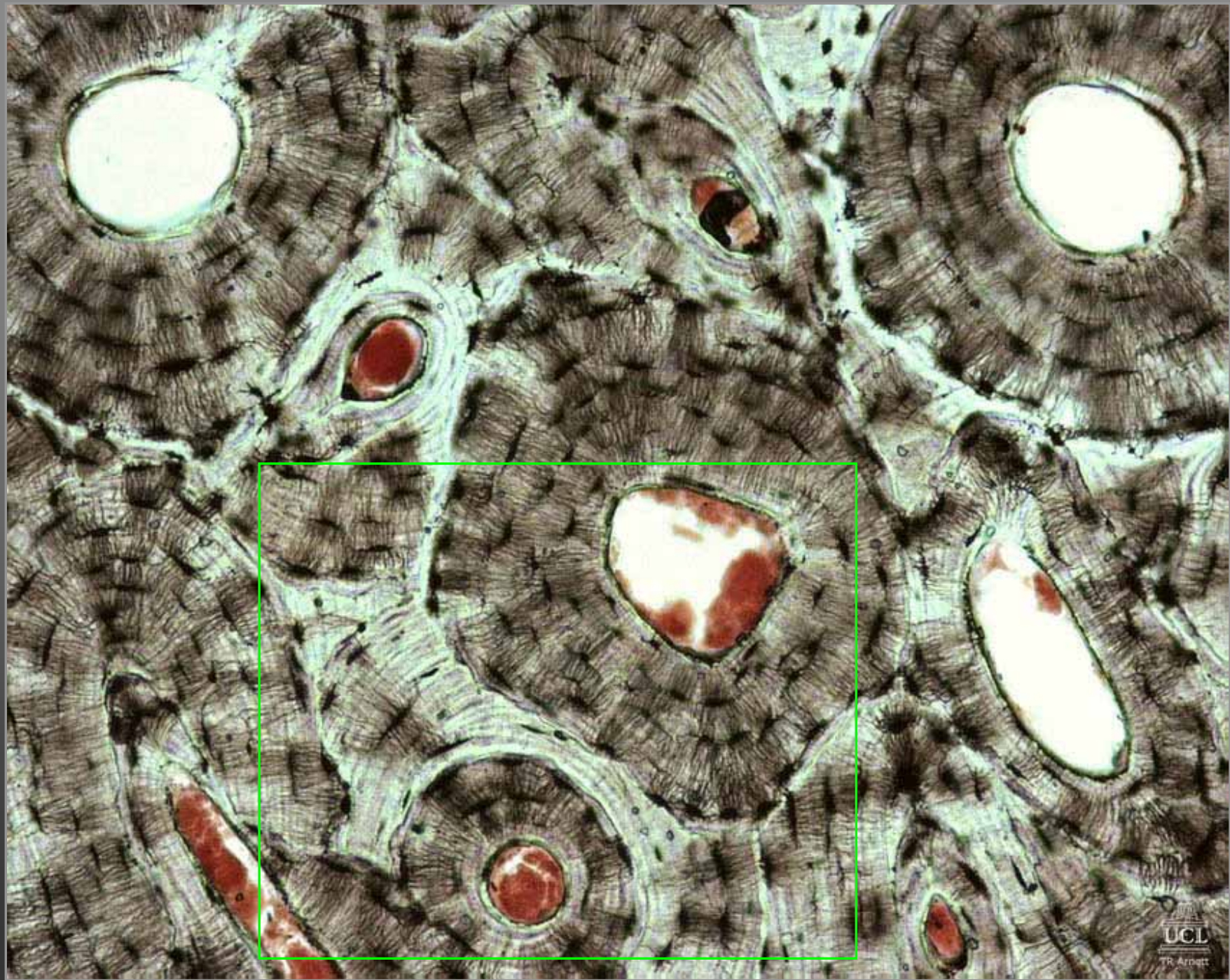


Osteonal (Haversian) systems in human cortical (finger) bone





Osteocyte lacunae & canaliculae in human cortical (finger) bone

